



Evidence-Based Series 17-6 Version 2

A Quality Initiative of the
Program in Evidence-Based Care (PEBC), Cancer Care Ontario

Invasive Mediastinal Staging of Non-small Cell Lung Cancer

The Expert Panel on Invasive Mediastinal Staging of Non-small Cell Lung Cancer

An assessment conducted in January 2024 deferred the review of Evidence-Based Series (EBS) 17-6 Version 2. This means that the document remains current until it is assessed again next year. The PEBC has a formal and standardized process to ensure the currency of each document ([PEBC Assessment and Review Protocol](#))

EBS 17-6 Version 2 is comprised of 4 sections. You can access the summary and full report here: <https://www.cancercareontario.ca/en/guidelines-advice/types-of-cancer/2221>

- Section 1: Guideline Recommendations (ENDORSED)
- Section 2: Evidentiary Base
- Section 3: EBS Development Methods and External Review Process
- Section 4: Document Assessment and Review

May 3, 2018

For information about the PEBC and the most current version of all reports, please visit the CCO website at <http://www.cancercare.on.ca/> or contact the PEBC office at:
Phone: 905-527-4322 ext. 42822 Fax: 905-526-6755 E-mail: ccopgi@mcmaster.ca

Citation (Vancouver Style): Darling G, Dickie A, Malthaner R, Kennedy E, Tey R, Invasive Mediastinal Staging Expert Panel. Invasive mediastinal staging of non-small-cell lung cancer: a clinical practice guideline. Yusufuku K, Brown J, reviewers. Toronto (ON): Cancer Care Ontario; 2010 Oct 18 [Endorsed 2018 May]. Program in Evidence-based Care Evidence-based Series No.: 17-6 Version 2 ENDORSED.

Journal Citation (Vancouver Style): Darling G, Dickie A, Malthaner R, Kennedy E, Tey R. Invasive mediastinal staging of non small-cell lung cancer: a clinical practice guideline. *Curr Oncol*. 2011 Sep;18(6):e304-e309. Available from: <http://www.current-oncology.com/index.php/oncology/article/view/820>.

Guideline Report History

GUIDELINE VERSION	SYSTEMATIC REVIEW		PUBLICATIONS	NOTES and KEY CHANGES
	Search Dates	Data		
Original October 2010	2006 to August 2010	Full Report	Peer review publication Web publication	NA
Current Version 2 May 2018	2010 to Feb 2018	New data found in Section 4: Document Assessment and Review	Updated web publication	2010 recommendations are ENDORSED



Evidence-Based Series 17-6 Version 2: Section 1

**Invasive Mediastinal Staging of Non-small Cell Lung Cancer:
Guideline Recommendations**

*G. Darling, J. Dickie, R. Malthaner, E. Kennedy,
and the Invasive Mediastinal Staging Expert Panel*

A Collaboration of Cancer Care Ontario's (CCO)
Program in Evidence-Based Care (PEBC) and Surgical Oncology Program (SOP)

Original Report Date: October 18, 2010

The 2010 guideline recommendations are

ENDORSED

This means that the recommendations are still current and relevant for decision making

*Please see Section 4: Document Assessment and Review for a summary of updated
evidence published between 2010 and 2018 and for details on how this Clinical Practice
Guideline was ENDORSED*

QUESTIONS

Primary Questions

Is invasive mediastinal staging in stage cT1-4, N0-3, M0 non-small cell lung cancer (NSCLC) patients indicated under the following circumstances?

- a) Normal-sized mediastinal lymph nodes on computed tomography scan (CT), and
 - i. negative positron emission tomography (PET)-CT scan in the mediastinum
 - ii. positive PET-CT in the mediastinum
- b) Enlarged discrete mediastinal nodes on CT (clinical N2 or N3 nodes), and
 - i. negative PET-CT in the mediastinum
 - ii. positive PET-CT in the mediastinum

Secondary Questions

What constitutes invasive mediastinal staging? What is the proper technique in performing invasive mediastinal staging?

- a) Which node stations should be biopsied?
- b) How many lymph nodes should be biopsied?

TARGET POPULATION

NSCLC patients in Ontario who have been clinically staged T1-4, N0-3, with no distant metastases.

INTENDED USERS

Thoracic surgeons, respirologists, and medical as well as radiation oncologists who treat lung cancer.

BACKGROUND

Methods

To answer the primary questions, a systematic review of existing guidelines and primary studies, and a consensus of interpretation of evidence by the members of the Invasive Mediastinal Staging Working Group (the Working Group) and the corresponding Expert Panel were used to formulate the recommendation. To answer the secondary questions, a non-systematic search of the evidence and consensus of expert opinion was used to formulate the recommendations. Please see Section 2 for details of the review methodology.

Clinical Perspective

The Working Group constructed the questions around CT and PET-CT scans, which were assumed to be standards of care for non-invasive staging. Recognizing that there are many available options and standards involved, the Working Group has chosen the following criteria for clinical consideration. Enlargement is defined as a short-axis lymph node diameter of ≥ 1 cm on a transverse CT scan. Quantitative assessments of PET-CT scans have been undertaken, with a comparison based on the uptake in the lesion in question compared with background activity of the lung and liver. Standardized uptake value (SUV) is calculated as the ratio of the activity in the tissue to the decay-corrected activity injected into the patient, normalized for patient body weight (2). SUV of ^{18}F Fluorodeoxyglucose (FDG) of less than or equal to 2.5 as a cut-off for normalcy is used in some studies (1). The Working Group felt that this guideline presents the best available evidence and does not expect higher level evidence to emerge in the near future. Thus, recommendations are provided for the following groups:

Group A: Normal sized mediastinal lymph nodes (MLN) on CT, and

- A1. negative PET-CT scan in the mediastinum. The recommendations for this pathway depend on the location of the primary tumour and tumour stage. Patients with central tumours can be grouped with those who have N1 disease because it is usually difficult to assess the N1 nodes separately in such cases.
- A2. positive PET-CT in the mediastinum

Group B: Enlarged (≥ 1 cm) discrete ipsilateral (N2) or contralateral (N3) MLNs on CT, and

- B1. negative PET-CT in the mediastinum
- B2. positive PET-CT in the mediastinum

In developing these recommendations, the Panel considered that, although PET has a higher sensitivity and specificity for evaluation of mediastinal lymph nodes compared to CT, the accuracy of PET depends on the size of mediastinal lymph nodes. Up to 25% of lymph nodes identified by PET as malignant are falsely positive. Hence pathologic confirmation of

malignancy is required so that the patient is not denied potentially curative therapy. In contrast, for normal-sized lymph nodes, PET has lower sensitivity (82%-93%). The estimated false-negative (FN) rate for a PET scan in the setting of normal-sized nodes is 20%. In a clinical setting where the probability of mediastinal lymph node metastases is increased, pathologic confirmation that the mediastinal lymph nodes are negative is required to avoid subjecting the patient to a futile (noncurative) lung resection (5).

RECOMMENDATIONS

Based on evidence from the American Association of Chest Physicians (ACCP) guideline (3) and primary literature from the systematic search:

- Invasive mediastinal staging is not needed in the case of normal-sized MLN on CT, a negative PET-CT scan, a peripheral clinical stage 1A tumour, and a negative clinical evaluation.
 - clinical stage 1A tumour defined as T1N0M0
 - T1: primary tumour diameter of 3 cm or smaller and surrounded by lung or visceral pleura or endobronchial tumour distal to the lobar bronchus
 - N0: no lymph nodes involved
 - M0: no metastases
- Invasive staging is recommended in the following cases:
 - Normal-sized MLN on CT with negative mediastinal PET-CT, and
 - the presence of a central tumour (tumour in the central third of the hemithorax), or
 - suspected N1 disease (enlarged N1 nodes and/or positive N1 nodes on PET-CT), or
 - T2 or greater tumours
 - Enlarged discrete MLN on CT (N2, N3), and negative or positive PET-CT
 - CT negative and PET positive in the mediastinum
- Invasive staging is important to confirm PET findings
- Appendix 1, Figure 1 illustrates the corresponding algorithm for these recommendations.

Based on a consensus of expert opinion:

- Five nodal stations (2R/L, 4R/L, and 7) should routinely be examined when performing invasive mediastinal staging, with at least one node sampled from each station unless none are present after actual dissection in the region of a particular nodal station
- Any enlarged or suspicious node should be biopsied
- Mediastinoscopy is the gold standard for invasive staging of the mediastinum. Endobronchial ultrasound-guided transbronchial needle aspiration (EBUS-TBNA) may be useful, but more data are required before it may be considered as an equivalent procedure.

Qualifying Statement - Added to the 2018 Endorsement:

- *There is important new guidance in the use of EBUS-TBNA, as highlighted in the 2013 ACCP guideline [10]:*

“In patients with high suspicion of N2,3 involvement, either by discrete mediastinal lymph node enlargement or PET uptake (and no distant metastases), a needle technique (endobronchial ultrasound [EBUS]-needle aspiration [NA], EUS-NA or combined EBUS/EUS-NA) is recommended over surgical staging as a best first test (Grade 1B).

In patients with an intermediate suspicion of N2,3 involvement, i.e., a radiographically normal mediastinum (by CT and PET) and a central tumor or N1 lymph node enlargement (and no distant metastases), a

needle technique (EBUS-NA, EUS-NA or combined EBUS/EUS-NA) is suggested over surgical staging as a best first test (Grade 2B). This recommendation is based on the availability of these technologies (EBUS-NA, EUS-NA or combined EBUS/EUS-NA) and the appropriate experience and skill of the operator.”

- *The 2013 ACCP evidence base covers evidence up to the end of 2012. More recently, a meta-analysis (covering comparative studies published up to March 2016) estimated the pooled risk-difference of the sensitivity of EBUS/EUS versus mediastinoscopy in cohort studies and RCTs at 0.11 (95% CI -0.07 to 0.29) and 0.11 (95% CI -0.03 to 0.25), respectively, suggesting equivalence of the two procedures. The complication rate was significantly lower with endosonographic procedures [11]. There are no studies past March 2016 directly comparing EBUS/EUS to mediastinal staging.*

KEY EVIDENCE

Invasive Staging Not Required

Normal CT, negative PET-CT, and a peripheral clinical stage 1A tumour:

- The ACCP systematic review found that the FN rate of CT in the group of patients with T1 tumours (i.e., clinical stage 1A) is approximately 9% (3).
- The Scottish Intercollegiate Guidelines Network (SIGN) recommends that patients with *small* peripheral tumours and a negative CT scan of the mediastinum require no further investigation, because the rate of false negatives in all categories of patients with lung cancer is 13% (7). SIGN does not provide a definition of small, but it may be equivalent to a clinical stage 1A tumour. The European Society of Thoracic Surgeons (ESTS) does not recommend mediastinoscopy in the case of a “T1 squamous cell tumour with N0 disease on CT scan” (8), based on the results of the SIGN systematic review.
- A negative PET-CT scan in the mediastinum carries an FN rate of approximately 5% (range 3% to 6%).

Invasive Staging Recommended

Normal CT, negative PET-CT and a central tumour, N1 disease or a T2 tumour or higher:

- The ACCP systematic review found the FN rate of CT scan in the mediastinum for patients with a central tumour is 20% to 25% (3). The same review found more limited data showing that the FN rate for PET-CT scanning in the mediastinum is similarly high (24% to 83%).
- Another systematic review found an FN rate of 22% with central tumours for a CT scan in the assessment of mediastinal nodes (4).

Additional evidence published since the ACCP guidelines:

- Cerfolio et al. (6) found that patients with clinical N1 disease suggested by integrated PET-CT/CT had a relatively high incidence (17.6% after mediastinoscopy and 23.5% after endoscopic ultrasound-guided fine needle aspiration [EUS-FNA]) of unsuspected N2 disease.

Enlarged lymph nodes on CT and PET-CT positive or negative:

- The PET-CT FN rate is estimated to be 13% to 25% in patients with nodal enlargement detected by CT scan, according to two meta-analyses. These estimates were based on indirect data and patient groups that were not clearly defined. Direct data from studies in patients with mediastinal or hilar node enlargement have found a PET-CT FN rate of 20% to 28% for N2,3 involvement.

- PET-CT scanning has been shown to falsely identify malignancy in approximately one fourth of patients with nodes that are enlarged for other reasons, usually due to inflammation or infection.(5)

Qualifying Statements

- Although there is no direct evidence, based on the International Association for the Study of Lung Cancer (IASLC) staging project showing adverse prognosis of larger tumours, the working group believes that T2 tumours should undergo invasive staging.
- In addition to tumour location (i.e., central versus [vs.] peripheral), several other factors have been noted in the literature as potentially affecting the likelihood of N2 disease, including maximum SUV (maxSUV) of the primary tumour (non-FDG avid primary tumours), tumour histology, degree of differentiation, and size, and bronchoalveolar cell carcinoma. These factors should be taken into account when deciding whether to perform invasive staging.
- Mediastinoscopy continues to be the gold standard for invasive mediastinal staging, but newer techniques such as EBUS-TBNA and EUS-FNA have shown promise. Monitoring of the literature in this field is recommended as information on the performance of newer staging techniques continues to accumulate. Please see the discussion in Section 2 for more details.

FUTURE RESEARCH

Yasufuku et al. (2007) (9) have a study in progress that compares mediastinoscopy and EBUS-TBNA in the same patients. We anticipate that the results of this study will add to the body of literature on the performance characteristics of EBUS-TBNA. Further details can be found at: <http://clinicaltrials.gov/ct2/show/NCT00372203>.

Funding

The PEBC is a provincial initiative of Cancer Care Ontario supported by the Ontario Ministry of Health and Long-Term Care through Cancer Care Ontario. All work produced by the PEBC is editorially independent from its funding source.

Copyright

This report is copyrighted by Cancer Care Ontario; the report and the illustrations herein may not be reproduced without the express written permission of Cancer Care Ontario. Cancer Care Ontario reserves the right at any time, and at its sole discretion, to change or revoke this authorization.

Disclaimer

Care has been taken in the preparation of the information contained in this report. Nonetheless, any person seeking to apply or consult the report is expected to use independent medical judgment in the context of individual clinical circumstances or seek out the supervision of a qualified clinician. Cancer Care Ontario makes no representation or guarantees of any kind whatsoever regarding the report content or use or application and disclaims any responsibility for its application or use in any way.

Contact Information

For further information about this report, please contact:

Dr. Gail Darling, Toronto General Hospital

200 Elizabeth St. 9N955, Toronto, ON M5G 2C4

Phone: 416-340-3121 Fax: 416 340-3660 E-mail: gail.darling@uhn.on.ca

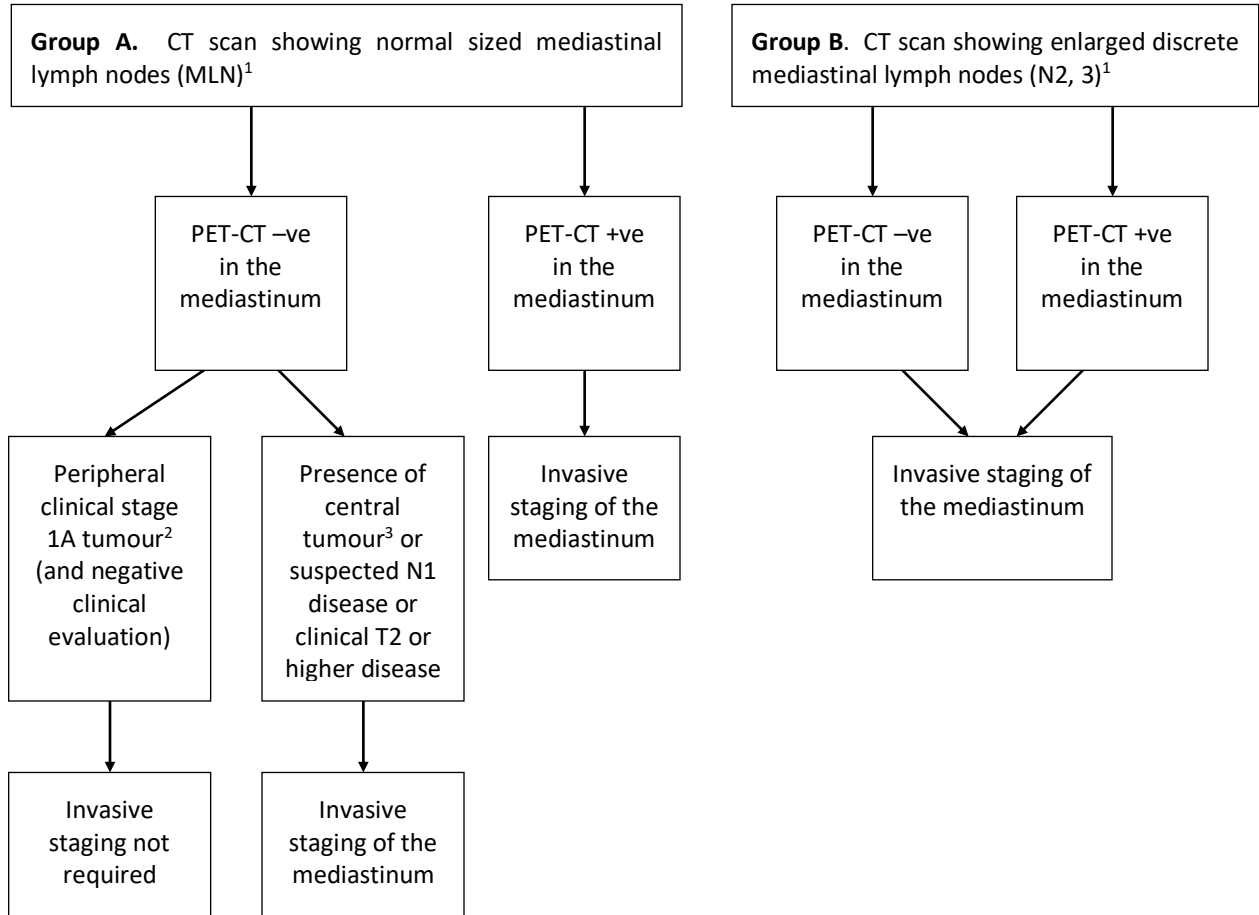
For information about the PEBC and the most current version of all reports, please visit the CCO Web site at <http://www.cancercare.on.ca/> or contact the PEBC office at:

Phone: 905-527-4322 ext. 42822 Fax: 905-526-6755

REFERENCES

1. Herth FJF, Eberhardt R, Krasnik M, Ernst A. Endobronchial ultrasound-guided transbronchial needle aspiration of lymph nodes in the radiologically and positron emission tomography-normal mediastinum in patients with lung cancer. *Chest*. 2008;133(4):887-91.
2. Al-Sarraf N, Gately K, Lucey J, Wilson L, McGovern E, Young V. Lymph node staging by means of positron emission tomography is less accurate in non-small cell lung cancer patients with enlarged lymph nodes: analysis of 1,145 lymph nodes. *Lung Cancer*. 2008 Apr;60(1):62-8.
3. Detterbeck FC, Jantz MA, Wallace M, Vansteenkiste J, Silvestri GA. Invasive mediastinal staging of lung cancer: ACCP evidence-based clinical practice guidelines (2nd edition). *Chest*. 2007 Sep;132(3 Suppl):202S-205S.
4. Ghosh S, Nanjiah P, Dunning J. Should all patients with non-small cell lung cancer who are surgical candidates have cervical mediastinoscopy preoperatively? *Interact Cardiovasc Thorac Surg*. 2006 Feb 1;5(1):20-4.
5. Silvestri GA, Gould MK, Margolis ML, Tanoue LT, McCrory D, Toloza E, et al. Noninvasive staging of non-small cell lung cancer: ACCP evidenced-based clinical practice guidelines (2nd edition). *Chest*. 2007 Sep;132(3 Suppl):178S-201S.
6. Cerfolio RJ, Bryant AS, Eloubeidi MA. Routine mediastinoscopy and esophageal ultrasound fine-needle aspiration in patients with non-small cell lung cancer who are clinically N2 negative: a prospective study. *Chest*. 2006 Dec;130(6):1791-5.
7. Scottish Intercollegiate Guidelines Network. Management of patients with lung cancer. A national clinical guideline. Edinburgh: Scottish Intercollegiate Guidelines Network; 2005 Feb.
8. De Leyn P, Lardinois D, Van Schil PE, Rami-Porta R, Passlick B, Zielinski M, et al. ESTS guidelines for preoperative lymph node staging for non-small cell lung cancer. *Eur J Cardiothorac Surg*. 2007 Jul;32(1):1-8.
9. Yasufuku K, Quadri M, dePerrot M. A prospective controlled trial of endobronchial ultrasound guided transbronchial needle aspiration compared to mediastinoscopy for mediastinal lymph node staging of lung cancer [abstract presentation]. Western Thoracic Surgical Association 33rd Annual Meeting; 2007 Jun 24-30; Santa Ana Pueblo NM; 2007.
10. Silvestri GA, Gonzalez AV, Jantz MA, Margolis ML, Gould MK, Tanoue LT, Harris LJ, Detterbeck FC. Methods for staging non-small cell lung cancer: Diagnosis and management of lung cancer, 3rd ed: American College of Chest Physicians evidence-based clinical practice guidelines. *Chest*. 2013 May;143(5 Suppl):e211S-e250S.
11. Sehgal IS, Dhooria S, Aggarwal AN, Behera D, Agarwal R. Endosonography Versus Mediastinoscopy in Mediastinal Staging of Lung Cancer: Systematic Review and Meta-Analysis. *Ann Thorac Surg*. 2016 Nov;102(5):1747-1755.

Appendix 1. Figure 1. Invasive mediastinal staging recommendations.



¹ This algorithm applies to the target population of NSCLC patients in Ontario who have been clinically staged T1-4, N0-3, with no distant metastases.

² Stage 1A: T1N0M0 (T1: primary tumour diameter of 3 cm or smaller and surrounded by lung or visceral pleura or endobronchial tumour distal to the lobar bronchus; N0: no lymph nodes involved; M0: no metastases).

³ For the purposes of this guideline, a tumour in the central third of the hemithorax is considered central. A tumour in the distal two-thirds of the hemithorax is considered peripheral.

